

# Severe airway injury due to alendronate aspiration

Paul MacEachern MD<sup>1</sup>, Aiden Brazil MD<sup>2</sup>, Alain Tremblay MDDM<sup>1</sup>,  
David R Stather MD<sup>1</sup>, Alex C Chee MD<sup>1</sup>, Julie Chou MD<sup>1</sup>

P MacEachern, A Brazil, A Tremblay, DR Stather, AC Chee, J Chou. Severe airway injury due to alendronate aspiration. *Can Respir J* 2013;20(6):410-412.

Sequelae of foreign body aspiration can range from clinically silent and asymptomatic to immediate asphyxiation and death. Only two previous cases of bisphosphonate tablet aspiration have been reported. Ulcerative esophagitis, a known adverse effect of oral bisphosphonate formulations, occurs primarily with prolonged exposure of esophageal mucosa to the medication. Little is known about the effects of bisphosphonates on the airway mucosa. The authors present a case involving an 84-year-old woman who required multiple bronchoscopic debridements, intubation for airway protection and intensive care unit admission following airway injury believed to be due to delayed recognition of aspiration of an alendronate tablet.

**Key Words:** *Aspiration; Bisphosphonate; Bronchoscopy; Foreign body*

### Learning objectives:

- Recognize that bisphosphonate aspiration may lead to more severe airway injury than other aspirated foreign bodies.
- Understand that in cases of suspected bisphosphonate aspiration, physicians should have a low threshold to directly visualize the airways as soon as possible.

### CanMEDS Competency: Medical Expert

### Pretest:

- What factors influence the degree of mucosal injury with bisphosphonate aspiration?

### CASE PRESENTATION

An 84-year-old woman in a rehabilitation facility for a recent hip fracture was prescribed alendronate (Fosamax, Merck, USA). The patient reported a choking episode after attempting to swallow a 70 mg alendronate tablet. The patient had no history of dysphagia, but admitted to not sitting upright when attempting to swallow the medication. She subsequently developed symptoms of hoarseness and cough. She sought medical attention the following day but her presentation was treated as an exacerbation of chronic obstructive pulmonary disease. She experienced no symptoms of infection and reported no sick contacts preceding these symptoms. Progressive worsening of cough, hoarseness and severe dyspnea led to a second hospital visit on postaspiration day 3.

Her medical history included osteoporosis, hypertension, dyslipidemia, a remote hysterectomy and remote cholecystectomy. She had no previous lung disease. Her medications included enalapril, pravastatin, gabapentin, amlodipine, acetylsalicylic acid and hydrochlorothiazide. She had quit smoking several years previously.

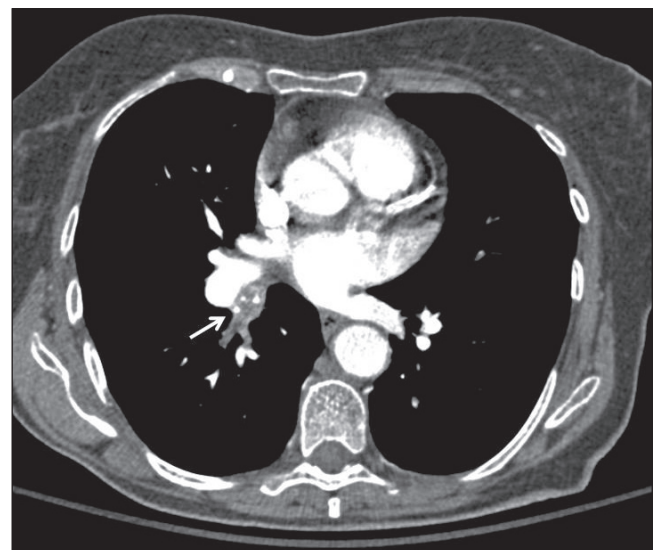
On presentation, she was in distress, tachycardic (heart rate 136 beats/min) and tachypnic (respiratory rate 25 to 50 breaths/min), with moderate accessory muscle use. High-flow oxygen (70%) via nonbreathing face mask was required to maintain normal oxygen saturation. On

## De graves lésions des voies aériennes en raison de l'aspiration d'alendronate

Les séquelles de l'aspiration d'un corps étranger peuvent être silencieuses et asymptomatiques sur le plan clinique, mais peuvent aller jusqu'à une asphyxie immédiate et à la mort. Seulement deux cas d'aspiration de comprimé de bisphosphonate ont déjà été signalés. L'oesophagite ulcéraire, un effet indésirable connu des formulations de bisphosphonate oral, se produit surtout en raison d'une exposition prolongée de la muqueuse œsophagienne au médicament. On ne sait pas grand-chose des effets des bisphosphonates sur la muqueuse des voies aériennes. Les auteurs présentent le cas d'une femme de 84 ans qui a dû se soumettre à de multiples débridements bronchoscopiques, à une intubation pour protéger ses voies aériennes et une hospitalisation aux soins intensifs après une lésion des voies aériennes qu'on croit causée par le délai à constater l'aspiration d'un comprimé d'alendronate.

auscultation of the chest, bilateral diffuse inspiratory and expiratory wheezes were heard. She also exhibited profound rhonchi. The remainder of the physical examination was unremarkable. Computed tomography of the chest revealed mucous mixed with hyperdense areas suggestive of particulate matter, plugging the right main stem bronchus and bronchus intermedius (Figure 1). A diagnosis of aspirated foreign body (alendronate tablet) was made.

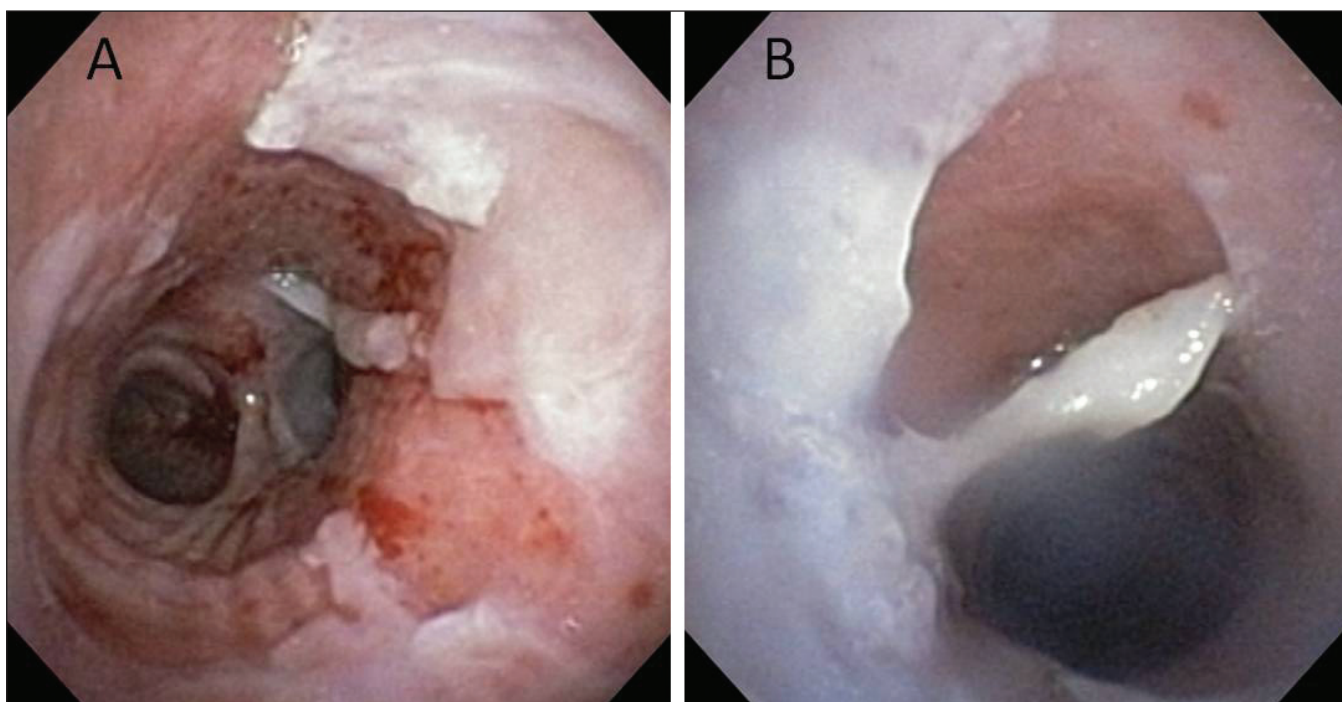
The patient was administered corticosteroids and antibiotics. Oxygen requirements improved to require 5 L/min by nasal canula. Flexible bronchoscopy was performed and the patient was found to have pseudomembranous matter overlying the upper larynx, vocal



**Figure 1)** Computed tomography scan showing mucous impaction and calcified particulate matter in the distal bronchus intermedius (arrow)

<sup>1</sup>Division of Respiratory Medicine, Department of Medicine; <sup>2</sup>Department of Medicine, University of Calgary, Calgary, Alberta

Correspondence: Dr Paul MacEachern, University of Calgary, Divisions of Respiriology and Medical Oncology, 3330 Hospital Drive Northwest, Calgary, Alberta T2N 4N1. Telephone 403-220-6882, fax 403-283-6151, e-mail pmaceac@ucalgary.ca



**Figure 2** A Trachea showing pseudomembranes and underlying inflammation and edema after partial debridement. Carina are apparent in the distance. B Flap of sloughed mucosa that would intermittently cause total occlusion of trachea

cords, trachea and right main stem bronchus (Figure 2A) completely occluding the bronchus intermedius. The pseudomembranes appeared to be injured airway mucosa, sloughing off intermittently and occluding the tracheal lumen (Figure 2B). Mechanical debridement using biopsy forceps to peel off dead tissue from the airway wall was performed. The underlying mucosa appeared to be inflamed and edematous. Once debrided, the right middle lobe and right lower lobe bronchi were visualized and both appeared to be narrowed. The left-sided airways appeared to be normal. The patient was admitted to hospital for ongoing observation.

Two days later (day 5 postaspiration), the patient suddenly developed increasing dyspnea and stridor. A repeat flexible bronchoscopy again revealed circumferential mucosal sloughing extending from the proximal trachea to the carina and into the right-sided airways. Mobile pseudomembranous material was visualized in the airway lumen causing intermittent complete obstruction and was believed to be the cause of her acute worsening. This was immediately debrided with forceps; however, a new 50% subglottic stenosis was also noted. This prompted transfer to the operating room for further debridement with flexible bronchoscopy via laryngeal mask, with rigid bronchoscopy equipment immediately available if needed. Following debridement, the patient was intubated for airway protection and monitored in the intensive care unit. On postaspiration day 7, bronchoscopy revealed reduced airway secretions and less mucosal inflammation. Her right middle and lower lobe bronchi remained narrowed but were patent. A cuff leak was noted. Postaspiration day 8, an improvement of the subglottic stenosis to 25% was noted and she was successfully extubated in the operating room. Corticosteroids were then discontinued after a total of seven days of 40 mg of prednisone. Before returning to her inpatient rehabilitation facility, the patient remained hospitalized for an additional five days, with ongoing hoarseness and improving stridor but without further dyspnea. Discharge instructions included a soft chew diet after formal assessment of her swallowing function.

On outpatient follow-up four weeks after discharge, her hoarseness, stridor and dyspnea had fully resolved. Chest x-ray was normal. Bronchoscopy three months after the initial injury demonstrated completely normal airways with no inflammation or airway narrowing. She had discontinued alendronate.

## DISCUSSION

Bisphosphonates have been used to reduce the morbidity and risk of fracture due to postmenopausal osteoporosis. Since approval, postmarketing research has shown adverse effects of oral bisphosphonate formulations including ulcerative esophagitis, which primarily occurs with prolonged exposure of esophageal mucosa to the medication (1). To reduce the potential for esophageal irritation, it is recommended that patients take the medication with water and not lie down for at least 30 min and until after the first food of the day (2).

Foreign body aspiration can have sequelae ranging from clinically silent and asymptomatic to immediate asphyxiation and death. Only two previous cases of bisphosphonate tablet aspiration have been reported. These events caused transient severe airway damage and compromise (3,4).

The present case represents an unexpected but serious adverse event in the treatment of postmenopausal osteoporosis. Without previous experience in tracheobronchial injury due to bisphosphonates, the clinical team consulted the literature for similar cases, finding only two published or presented at scientific meetings. One case identified pre-existing dysphagia; the other made no mention of risk factors for aspiration (3,4). Both patients recovered fully after discharge.

Direct esophageal injury by bisphosphonates is clearly established, with a variety of manifestations: most commonly ulceration and esophagitis and, occasionally, stricture. Recurring themes leading to esophageal complications include coexisting esophageal abnormalities, and failure to observe recommended precautions (ie, drinking water after taking their medication and remaining upright for 30 min). There is one published report of esophagitis dissecans superficialis associated with a bisphosphonate (5), which has a similar gross appearance to the bronchoscopic pseudomembrane findings of both our patient and of that reported by Kraft et al (3). The causes of these insults may be multifactorial, including prolonged direct mucosal contact, mucosal bathing of bisphosphonate-containing gastric juices, and irritation of pre-existing esophageal disease (6). In our patient, who had no history of gastroesophageal reflux disease and no indication of pre-existing tracheal disease, the most likely mechanism was injury from prolonged direct exposure to alendronate. We hypothesize that in our patient, the alendronate tablet lodged in the distal bronchus intermedius and airway

secretions caused it to disintegrate. The resulting pill sludge was likely coughed about, causing further contact with the airway mucosa and subsequent injury from the false cords down to the distal right-sided airways. An inability to completely remove the medication may have prolonged the contact and worsened the injury. It is unknown whether earlier recognition of the aspiration and prompt removal from the airway would have led to a less severe airway injury, although we speculate this may have been the case.

### SUMMARY

We presented a case involving a patient who required multiple bronchoscopic debridements, short-term intubation for airway protection and admission to the intensive care unit after severe airway injury due to alendronate aspiration. This is a rare but severe complication of alendronate. Prescribers of this medication need to weigh potential benefits against potential risks of its use. Currently, the product monograph recommends against its use in patients at increased risk for aspiration (2), a recommendation we support. Physicians prescribing alendronate should evaluate patients for the risk of aspiration and remind them of the necessary safety precautions. We also recommend that physicians encountering patients suspected of having aspirated alendronate should urgently arrange for direct visualization of the airways to inspect for complications and to remove any residual medication from further contact with the tracheobronchial mucosa. The propensity of delayed complications is unknown at this time.

#### Post-test:

The degree of esophageal mucosal injury from bisphosphonates is believed to be due to prolonged contact of the medication to the esophageal mucosa. It is likely that prolonged contact with airway mucosa will similarly lead to more severe airway injury in the case of aspiration.

---

**AUTHOR CONTRIBUTIONS:** Dr Paul MacEachern was the primary physician managing this case and performed all bronchoscopies and follow-up. He was involved with the writing and review of the manuscript. Dr Aiden Brazil assisted in managing this case. He performed background research and was involved with the writing and review of the manuscript. Dr Alain Tremblay was consulted on the management of this case and assisted with the writing and review of the manuscript. Dr David R Stather assisted with the writing and review of the manuscript. Dr Alex C Chee assisted with the writing and review of the manuscript. Dr Julie Chou assisted in management of this case and was involved with writing and review of the manuscript. This work was performed at the Division of Respiratory Medicine, University of Calgary, Calgary, Alberta.

---

### REFERENCES

1. de Groen PC, Lubbe DF, Hirsch LJ, et al. Esophagitis associated with the use of alendronate. *N Engl J Med* 1996;335:1016-21.
  2. Fosamax Product Monograph. Nov 24, 2011. Merck Canada Inc. <[www.merckfrosst.ca/assets/en/pdf/products/FOSAMAX-PM\\_E.pdf](http://www.merckfrosst.ca/assets/en/pdf/products/FOSAMAX-PM_E.pdf)> (Accessed January 7, 2013).
  3. Kraft B, Al-Jishi W, Gilstrap D, et al. Severe airway damage due to aspiration of an alendronate pill. *Chest* 2011;140:85A. (Abst)
  4. Jungblut SA, Frickmann H, Achenbach HJ, Wagner TO. [Damage to the respiratory tract due to aspirated alendronate.] *Pneumologie* 2007;61:771-3.
  5. Hokama A, Ihama Y, Nakamoto M, et al. Esophagitis dissecans superficialis associated with bisphosphonates. *Endoscopy* 2007;39(Suppl 1):E91.
  6. Peter CP, Handt LK, Smith SM. Esophageal irritation due to alendronate sodium tablets: Possible mechanisms. *Dig Dis Sci* 1988;43:1998-2002.
-